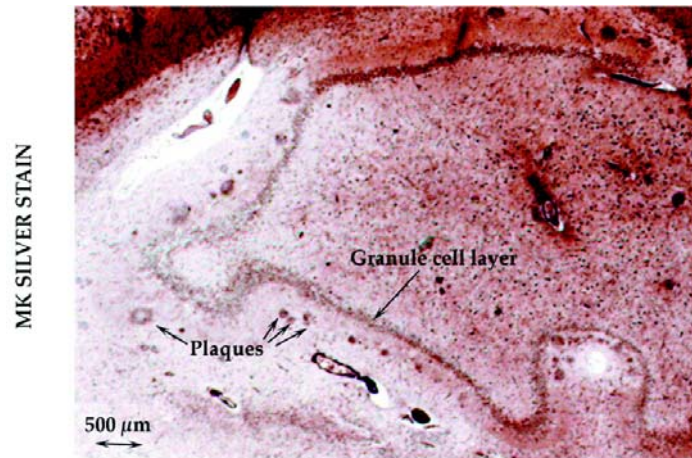
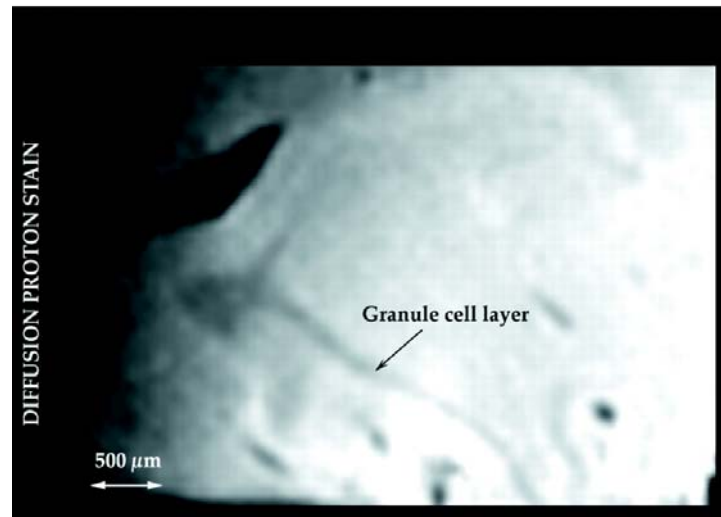


Micrographs of the Brain of a Person who Died of Alzheimer's Disease

Optical
Microscope



Magnetic Resonance
Image (MRI)



Benveniste, Helene et al. (1999) Proc. Natl. Acad. Sci. USA 96, 14079-14084